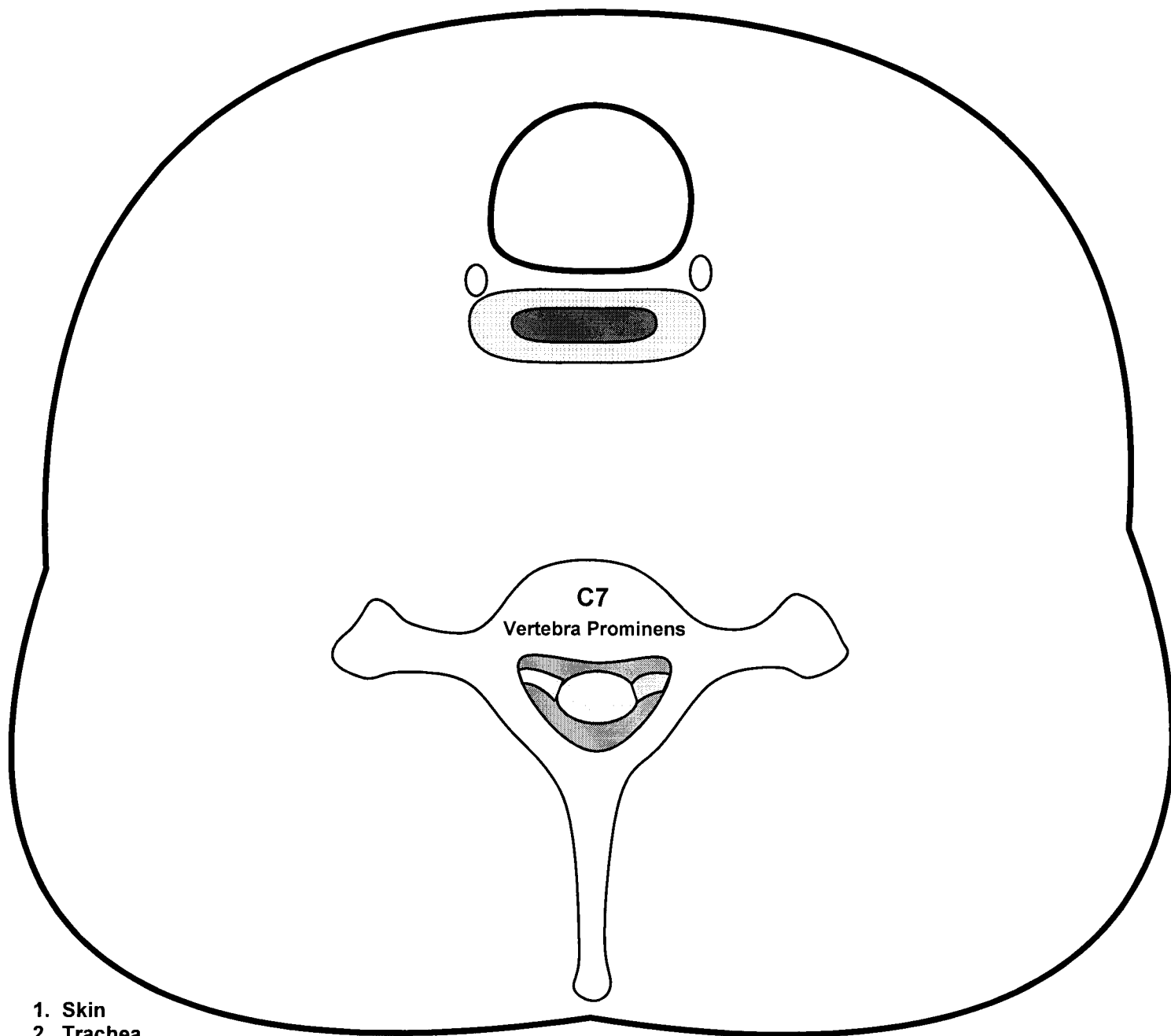
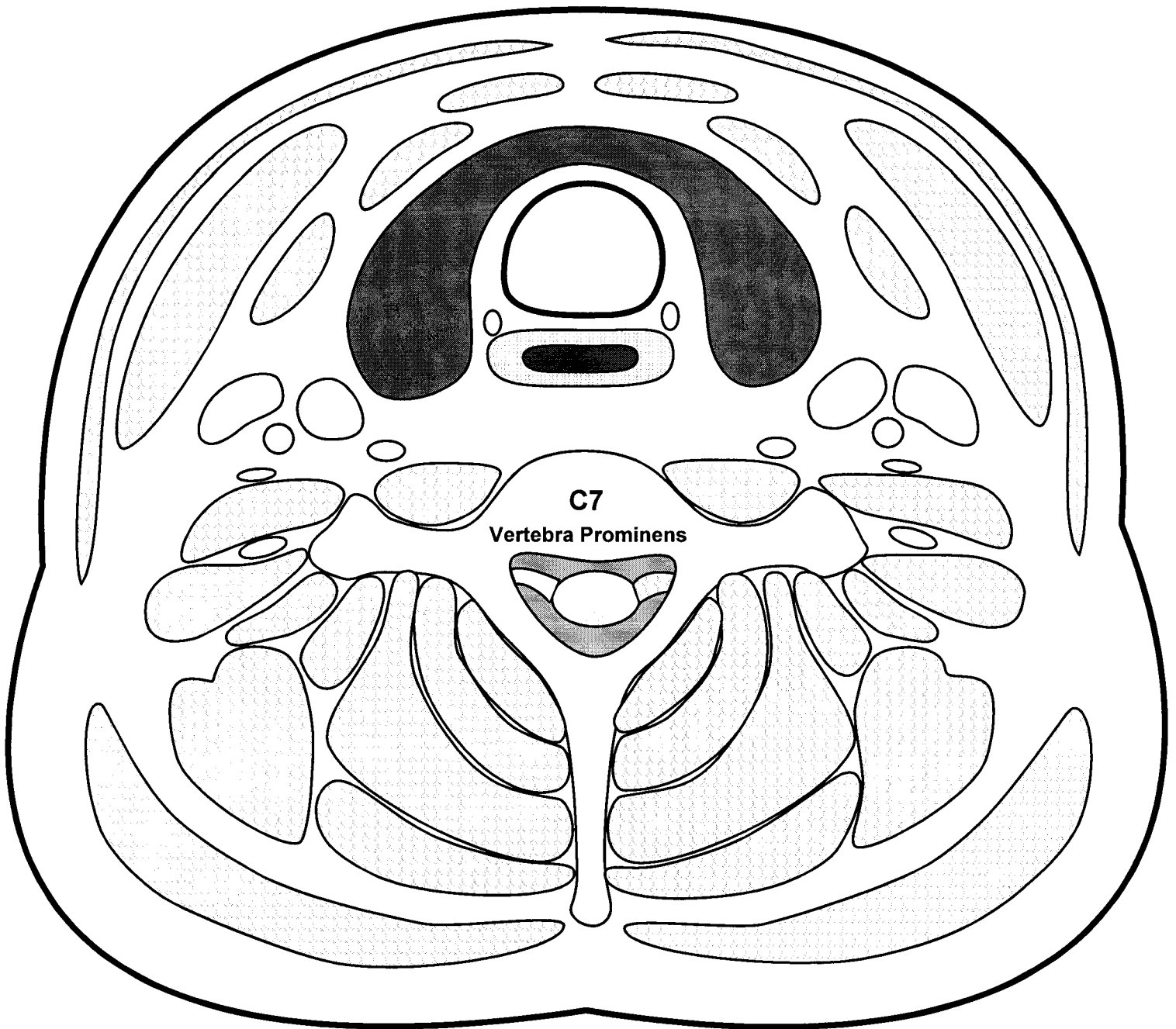


# Cervical Fascia (Cross Section) -- Fascial Spaces



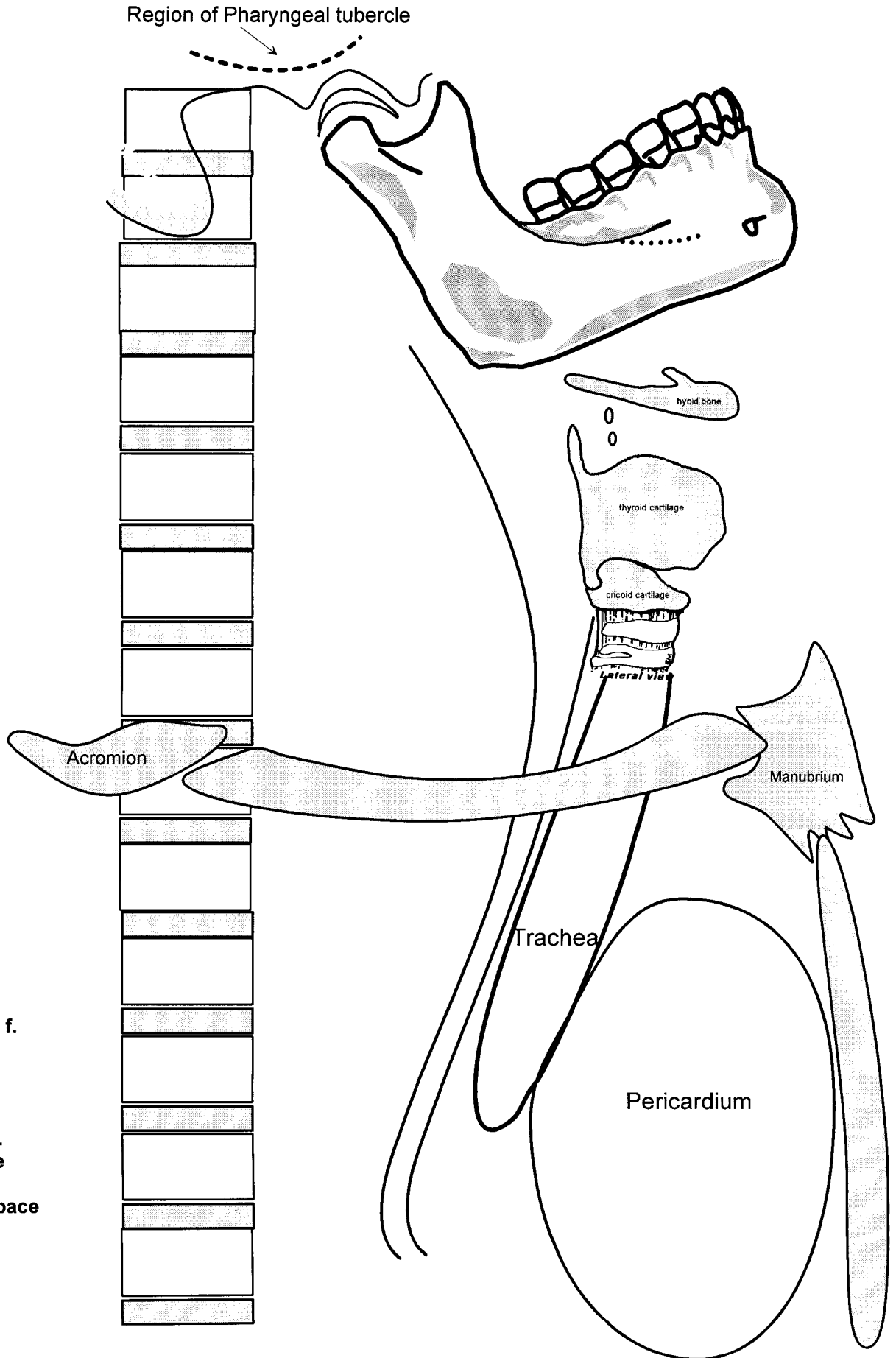
1. Skin
2. Trachea
3. Esophagus
4. Superficial cervical f.
5. Tela Subcutania
6. Prevertebral f.
7. Alar layer
8. Pretracheal f.
9. Buccopharyngeal f.
10. Carotid sheath
11. Internal jugular v.
12. Common carotid a.
13. Vagus n.
14. Pretracheal space
15. Retropharyngeal space
16. "Danger" space

# Fascial Layers of Neck



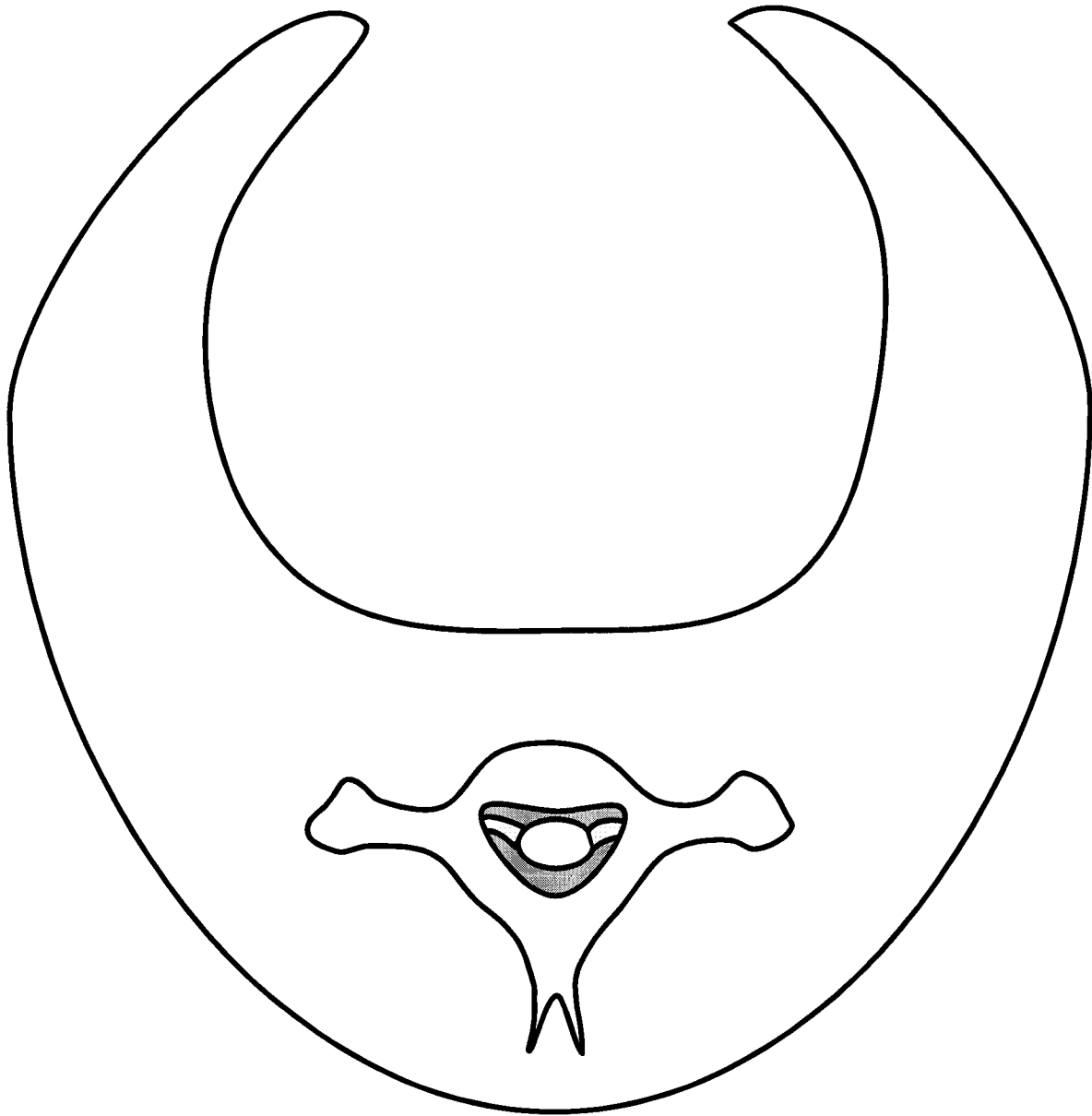
1. Platysma muscle
2. Sternocleidomastoid muscle
3. Trapezius muscle
4. Superficial investing (cervical) fascia
5. Prevertebral fascia
6. Alar fascia
7. Carotid sheath
8. Common carotid artery
9. Internal jugular vein
10. Vagus nerve (CN 10)
11. Pretracheal visceral fascia
12. Buccopharyngeal visceral fascia
13. Thyroid gland
14. Trachea
15. Esophagus
16. Recurrent laryngeal nerve
17. Retropharyngeal space (retrovisceral)
18. Levator Scapula
19. Scalenus anterior
20. Scalenus medius
21. Scalenus posterior
22. Ventral ramus brachial plexus (C8)
23. Phrenic Nerve
24. Sympathetic trunk
25. Sternohyoid muscle
26. Sternothyoid muscle
27. Omohyoid muscles (anterior belly)
28. "Danger Space"
29. Longus Colli Muscle
30. Pretracheal space

# Cervical Fascia - Saggital View



1. Skin
2. Trachea
3. Esophagus
4. Superficial cervical f.
5. Tela Subcutania
6. Prevertebral f.
7. Alar layer
8. Pretracheal f.
9. Buccopharyngeal f.
10. Suprasternal Space
11. Pretracheal space
12. Retropharyngeal space
13. "Danger" space

# Cervical Fascia - Cross Section Through Oropharynx



1. Skin
2. Oral mucosa
3. Buccopharyngeal fascia
4. Pharyngobasilar fascia
5. Pterygomandibular raphe
6. Median raphe of superior constrictor
7. Buccinator muscle
8. Superior constrictor muscle
9. Prevertebral fascia
10. Alar layer prevertebral fascia
11. Carotid sheath
12. Internal carotid artery
13. Retropharyngeal space
14. "Danger" space